

Flexible Small Spiral Drains in Cardiac Surgery. Experience in 150 patients.

Stefano Moriggia, Andrea Blasio, Chiara Calabrese, Ottavio Alfieri

Division of Cardiac Surgery

S.Raffaele University Hospital - IRCCS

Milan, Italy

Corresponding author:

Stefano Moriggia MD

Cardiac Surgery

San Raffaele Hospital

Via Olgettina 60, 20132 Milan, Italy

[*moriggia.stefano@hsr.it*](mailto:moriggia.stefano@hsr.it)

Phone +390226437108

Fax +39022643712

Abstract

Objective: to evaluate the performance of small calibre, flexible, spiral drain in patients undergoing general adult cardiac surgery especially including those with high risk of bleeding.

Methods: 150 consecutive patients who underwent all kind of cardiac surgery, received **small calibre (19F), flexible, fluted spiral drain with round cross-section.** Drains were connected to a unitized cardiac drainage system.

Results: The amount of fluid evacuated was 456.6 ± 200 ml. The drains were removed after a mean of 2 ± 3.4 days. Chest re-exploration had to be performed in one patient for drain rupture during removal maneuver. Three patients needed postoperative pericardial drainage for pericardial effusion and four patients required additional drain positioning for

pneumothorax. Conclusions: Spiral drains proved to be safe and effective in cardiac surgery, they allowed evacuation of large amounts of blood/fluid as well as air and were associated with minimal discomfort.

Introduction

In cardiac surgery semi-rigid plastic tubes (28F-32F) are commonly used to decompress the mediastinal and pleural spaces from fluid and air, to avoid hemodynamic impairment due to cardiac tamponade or tension pneumothorax and to prevent incomplete expansion of the lung caused by air and/or fluid besides the monitoring of postoperatively bleeding. Because of their size and rigidity, standard chest tubes may hinder postoperative recovery by limiting ambulation and deep breathing [1-2]. They have also been found to impair pulmonary function, especially when placed through an intercostal space and to interfere with the proper working of coronary bypass grafts. Compression of the grafts, suction and avulsion during removal maneuver are rare but severe and potentially life threatening complications [3-4].

Commonly flexible spiral drains are used in minimally invasive cardiac surgery into account of their small gauge, nevertheless their use in patients with high risk of bleeding has not yet been investigated.

We employed a type of small (19F) and flexible spiral drain in 150 patients to assess their effectiveness and possible use as a viable alternative to standard drainage, and evaluate their performance even in high risk for bleeding procedures.

Materials and methods

From May 2011 to February 2012, 150 consecutive patients, (96 male and 54 female) with a mean age of 55 ± 24 years, who had to undergo cardiac surgery were assigned to receive small (19F), fluted, flexible spiral drains with round cross-section (Spiral Drain, Redax® srl Mirandola, Modena, Italy).

The spiral drain is made of biocompatible radiopaque silicone with four helical channels along the center core. Drain components consist of a silicone spiral drainage section and a silicone extension tube (Fig.1-2).



Fig. 1. Spiral Drains are white, radiopaque silicone drains with four helical channels along the center core. Spiral profile helps to prevent kinking effect when drain is positioned in curved placements (with permission of Redax® srl Poggio Rusco Mantova, Italy).

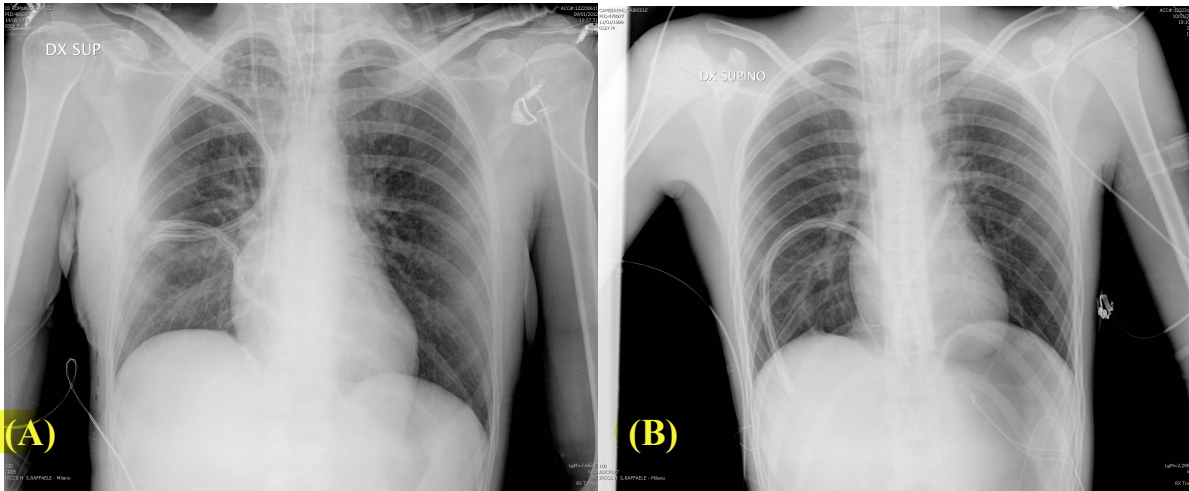


Fig. 2. Chest X-ray showing the drains position after MVR through a right mini-thoracotomy (A) and after CABG through a median sternotomy (B)

We used spiral drains in all kinds of cardiac surgery. As usual we inserted at least one retro-cardiac drain and one mediastinal drain after all procedures, pleural drains were placed when needed. The drains were connected to a unitized cardiac drainage system and put under aspiration, not differing from the usual setting used with semi-rigid drains. Chest tubes were observed by nurses and surgeon to check bleeding and the removal of fluid and air. The timing of spiral drains removal was determined on the basis of the same criteria used for the removal of standard drains: in the first day after the operation for CABG and valve repair/replacement; after 48/72 h for redo and/or thoracotomy. In-hospital chest radiograms were routinely performed on the first and second postoperative days and subsequently if dictated by individual patient's symptoms. To assess the safety of the spiral drain we examined a set of complications related to the use of chest tubes. These complications included: operative mortality, mediastinitis, re-operation due to bleeding, early and late cardiac tamponade and pneumothorax.

Early cardiac tamponade was defined as tamponade occurring while chest tubes were still in place. Late cardiac tamponade was defined as tamponade occurring after chest tubes drains were removed, but before discharge from the hospital.

Results

A total of 150 consecutive patients submitted to cardiac surgery, received spiral drains. Procedures performed are reported in table I.

CABG	34
Mitral Valve Repair	38
Mitral Valve Replacement	11
Aortic Valve Replacement	24
Mitro-Aortic Valve Replacement	4
Bentall	6
Left Ventricular Aneurismectomy (Dor procedure)	1
ECMO	1
Redo	14
Minimal invasive procedures	18 (minithoracotomy 12, ministernotomy 6)

The amount of fluid evacuated was 456.6 ± 200 ml . No cases of early cardiac tamponade occurred.

Four patients needed cardiac re-exploration for intensive bleeding.

Three patients underwent postoperative pericardial drainage for late cardiac tamponade, while four patients required additional chest drain for pneumothorax.

There was one case of drain rupture during removal maneuver that required chest re-exploration. The rupture was caused by a subcutaneous suture stitch transfixing the silicone extension tube. **No patients referred unusual drain-related pain.** Drains were removed after a mean of 2 ± 3.4 days.

Discussion

The placement of chest tubes following cardiac procedures is essential in decompressing the mediastinal and pleural spaces and preventing cardiac tamponade. Because of the serosanguineous nature of the fluid typically drained after cardiac operations, the use of large-bore, 28F to 32F rigid tubes has been the drainage modality of choice.

Although the conventional chest tube has been proven highly effective, it possesses unwanted features (large size and rigidity). In addition to providing a great degree of discomfort to the patient, the rigid conventional chest tubes may compress coronary structures and/or unsettle bypass grafts [3].

Anecdotally, patients seemed to experience less pain with the smaller drains and appeared to have greater freedom with sitting position and deambulation [5].

The spiral drain is a round fluted drain with spiral-shaped grooves to enhance the drainage efficacy. This advanced design offers the following advantages: provides more effective distribution of suction and fluid over the entire drain, improves collateral drainage by providing alternate pathways, minimizes aspiration of surrounding tissues and clot infiltration with spiral ducts [6-7]. The flexibility of spiral drain allows the surgeon to easily position this kind of tube with no risk of compression and damage of surrounding structures. This is an important issue especially in coronary surgery.

The spiral drains can be connected with a Y connector to a unitized cardiac drainage system under aspiration, so that the drains work by capillarity plus aspiration. Great care must be taken during the connection between the external part of the tubes and the drainage system, the length of the outside extension part of the tubes must be adjusted so as to avoid folds. Kinking of the outer portions of this kind of small chest tubes could be a

problem because of the impossibility to perform selective internal aspiration and clot removal. Very often the Y connection is beneath the bed linen and the hot air blanket so that additional monitoring must be performed during the first hours after surgery.

In our experience the spiral drains proved to be adequate even in patients with copious bleeding. The spiral design prevents kinking when the drain is positioned in curved placements. The handling of this kind of drains proved to be very useful in minimal invasive surgical approaches. Moreover the skin incisions to place spiral drains are smaller than those made for normal drains.

Finally at the economic analysis the utilization cost of the spiral drain system is comparable to the conventional chest tube since is not necessary to purchase curved drains which are more expensive.

The lack of a control group represents an important limitation in this study and the conclusions are observational only. Our aim was to make an initial experience with the use of this kind of chest tubes allowing the feasibility of further investigation. Indeed, after this preliminary data collection we feel that a more complete evaluation through a randomized study is necessary comparing patients with large rigid tubes and those with small tubes using specific quantitative parameters.

Patient's comfort by means of pain reduction, decreased use of analgesic drugs and increased motion capacity during physiotherapy has to be analyzed respectively with an on demand register of analgesic medications administration, a visual analog pain score and an exercise tolerance scale.

In conclusion, in our initial experience, spiral drains proved to be safe and effective, the complications observed should be considered normal and not drain-related, furthermore

they allowed evacuation of large amounts of blood/fluid as well as air and were associated with minimal discomfort.

References

[1] Hagl C, Harringer IAW, Gohrbandt B, et al.

Site of pleural drain insertion and early postoperative pulmonary function following coronary artery bypass grafting with internal mammary artery.

Chest 1999; 115:757-761

[2] Stolz AJ, Lischke R, Simonek J, Schützner J, Pafko P.

Rozhl Chir. 2005 Nov;84(11):529-32. Czech

Comparison study on the use of tubular and spiral thoracic drains following lung resections. A prospective study.

[3] Svedjeholm R, Hakanson E.

Postoperative myocardial ischemia caused by chest tube compression of vein graft.

Ann Thorac Surg 1997; 64:1806-1808

[4] Frankel, Timothy L; Hill, Peter C; Stamou, Sotiris C; Lowery, Robert C; et al

Silastic drains vs conventional chest tubes after coronary artery bypass.

Chest. 2003 Jul ;124(1):108-13.

[5] A. Terzi et al.

The use of flexible spiral drains after non-cardiac thoracic surgery. A clinical study.

Eur J Cardiothorac Surg 2005;27: 134-137

[6] Lancey RA et al.

The use of smaller, more flexible chest drains following open heart surgery. Chest
2001;119: 19-24

[7] Obney JA et al.

A method for mediastinal drainage after cardiac procedures using small silastic drains. Ann
Thorac Surg 2000;70: 1109-1110